

Prolotherapy and Achilles tendinopathy: A prospective pilot study of an old treatment

John Lyftogt, New Zealand

Abstract

Background. Prolotherapy has been successfully used for over 60 years in the treatment of a large variety of musculoskeletal conditions. No studies on prolotherapy and Achilles tendinopathy have been published.

Objective. This prospective pilot study assessed: (1) the clinical effectiveness of prolotherapy in the treatment of Achilles tendinopathy in a general medical/sports medicine setting with three-month follow up; (2) a postulated positive relationship between initial visual analogue scale (VAS) scores and number of treatments.

Patients and Methods. All 16 patients with 19 Achilles tendinopathies presenting over a 16-week period were included in the study. All patients were treated weekly with a standard prolotherapy solution of 20% dextrose and 0.1% lignocaine. Results were monitored with individual prolotherapy recovergrams which were compiled in a study recovergram.

Results. Fourteen patients were satisfied with the results of the treatment and returned to pre-injury levels of activity. One patient was referred for bilateral Haglund exostostomy and decompression surgery. One patient was not satisfied but was not available for follow up. Of the 14 Achilles tendinopathies reaching VAS=0 at the end of treatment, 11 remained at VAS=0 at follow up. The study-recovergram showed a positive correlation between initial VAS score and number of treatments.

Conclusions. Prolotherapy is a safe, effective, and cheap treatment for Achilles tendinopathy in this pilot study. Recovergrams are an effective clinical tool for monitoring progress, evaluating effect, and predicting duration of treatment.

Background

In the *British Medical Journal* editorial (16 March 2002)¹ the authors alert all medical practitioners dealing with

lateral and medial elbow pain, rotator cuff problems, achillodynia, patellar tendinopathy, and others, with the banner "Time to abandon the 'tendinitis' myth."

These conditions should be called "tendinosis" (or tendinopathy), as was first described in the *American Journal of Sports Medicine* in 1976.²

The authors finish the editorial by saying that "adopting the tendinopathy paradigm is essential if general practitioners are to practise evidence-based medicine. However, there remain many unanswered questions, particularly with respect to treatment."

Other researchers have responded with treatment trials and research in line with the new paradigm.^{3,4} Hence there is now a growing literature showing the beneficial effect of eccentric strengthening exercises in Achilles tendinopathy and also a new treatment by Swedish researchers with ultrasound-guided sclerosis of neovessels in painful chronic Achilles tendinopathy.⁵

Decompression surgery could also be considered to address tendinopathy along this paradigm, although it is generally viewed as a last resort treatment.

George Hackett,⁶ who first coined the term "prolotherapy" in the 1940s, carried out extensive animal studies on rabbit tendons, with proliferants showing an average increase in tendon diameter of 25-40% after 4-6 weeks of treatment. This resulted in an increased strength and load to failure, particularly at the fibro-osseous junction.

Like many prolotherapists, the author believes that prolotherapy is also an appropriate response to the paradigm of tendinopathy.

Patients and methods

All 16 patients (four women and 12 men) with 19 Achilles tendinopathies presenting over a 16-week period to Active Health, a sports medicine and rehabilitation clinic, were included in the pilot study.

All patients were either self-referred or referred by a sports medicine colleague specifically requesting prolotherapy. All patients except one had received extensive physiotherapy/eccentric strength exercises/acupuncture/podiatry, and many other treatment modalities without resolution. The median duration of symptoms was 14 months (range 0.5-600). Median age was 48 years (range 37-59).

In two patients the condition threatened their occupation (both police officers) and in 10 patients their participation in masters triathlon and running had ceased, causing an adverse effect to their overall health and well-being. The remaining four patients experienced difficulty with walking and/or reported night pain.

A distinction between insertional (3) and non-insertional (16) Achilles tendinopathy was made on clinical grounds. Insertional tendinopathy may well have a different etiology, as a common underlying Haglund exostosis causes compression injury to the anterior enthesis, ultimately requiring surgical removal of the exostosis. Confirmation of this diagnosis is with a lateral x-ray of the os calcis. One patient was referred for bilateral Haglund exostostomy. Non-insertional Achilles tendinopathy traditionally affects the 2-7 cm area proximal to the os calcis.

Prolotherapy was administered weekly where possible. The treated area was identified by palpation of the swollen and painful areas. Injection sites were marked 15 mm apart on the postero-lateral and postero-medial side of the tendon. A "bleb" of local anesthetic (lignocaine 2%) was injected in marked sites. Then 1 ml of prolotherapy diluent consisting of dextrose 20%/lignocaine 0.1% was injected very slowly into each site subcutaneously, carefully avoiding the paratenon. Even minor needle trauma of the paratenon causes prolonged pain, discouraging patient and practitioner alike. The aim is to achieve complete local anesthesia at the time of treatment as this indicates

Prolotherapy and Achilles tendinopathy

that all areas causing pain are treated.

Each patient was monitored with a recovergram recording pain VAS scores with 0 = no pain and 10 = worst imaginable pain. Once familiar, most patients volunteered their VAS score at the beginning of each consultation. Most VAS scores declined in a linear fashion, the exception usually caused by accidental needle trauma of the paratenon the previous week.

Results

Fourteen patients with 16 Achilles

tendinopathies were satisfied with the treatment.

One patient was not satisfied although his VAS score went down to 0. He was not available for follow up due to being stationed in Antarctica.

One patient with bilateral insertional Achilles tendinopathy was referred for surgery after receiving four treatments reducing his pain level from VAS 7 to 4 while waiting for surgery.

Of the satisfied 16 Achilles tendinopathies, 13 VAS scores went down to 0, with three at follow up going

respectively to a VAS score of 1, 2, and 3, and without return of previous disability. One patient with a 50-year history chose to stop after six treatments at VAS score 3 (down from 8) with no change at follow up and one patient interrupted her treatment for six months due to overseas travel. At the time of writing she had resumed her treatment and is now nearly pain free (VAS=1). One patient went from VAS 5 to 1 with same at follow up.

The study recovergram graphically demonstrates the outcome of

Prolotherapy Recovergram

(after Dr P Watson Aust Mus Med Nov 2000)

Name: GI

Date of onset: September 2003

Address:

Hx : Training for Masters World Champs Triathlon. Injured L Achilles. Has had several previous episodes of Achillodynia since age 20. Usually settled with rest and stretching. This episode treated with Physio x 30 and Acupuncture x 6.

Phone:

Age: 56

Sex: male

Occupation:

VAS: visual analogue scale 0=no pain 10=worst imaginable pain

| Year: | Month: | 4 | 4 | 5 | 5 | 5 | 5 | 6 | 6 | 6 | 6 | 7 | | | | F/U |
|-------|--------|----|----|---|----|----|----|---|---|----|----|---|--|--|--|-----|
| Day: | 6 | 20 | 27 | 4 | 11 | 19 | 25 | 1 | 8 | 16 | 22 | 6 | | | | 12 |
| 10 | | | | | | | | | | | | | | | | |
| 9 | | | | | | | | | | | | | | | | |
| 8 | | | | | | | | | | | | | | | | |
| 7 | x | | | | | | | | | | | | | | | |
| 6 | | | | | | | | | | | | | | | | |
| 5 | | x | x | | | | | | | | | | | | | |
| 4 | | | | x | x | | | | | | | | | | | |
| 3 | | | | | | x | x | | | | | | | | | |
| 2 | | | | | | | | x | | | | | | | | |
| 1 | | | | | | | | | x | x | x | | | | | |
| 0 | | | | | | | | | | | | x | | | | x |

ACTIVITIES LIMITED

| | | | | | | | | | | | | | | | | | |
|---------|---|--|---|---|---|---|--|---|---|---|---|---|---|---|--|--|---|
| Running | 2 | | 1 | 1 | 1 | 0 | | 1 | 1 | 1 | 0 | 0 | 0 | 0 | | | 0 |
| Walking | 1 | | 1 | 1 | 0 | 0 | | 0 | 0 | 0 | 0 | 0 | 0 | 0 | | | 0 |
| | | | | | | | | | | | | | | | | | |
| | | | | | | | | | | | | | | | | | |
| | | | | | | | | | | | | | | | | | |

Disability Rating:

0 = no limitation, 1 = can do slightly limited, 2 = can do with difficulty, 3 = can't do at all

Prolotherapy and Achilles tendinopathy

prolotherapy in this pilot study. It also illustrates the clinical experience that the initial pain VAS score is a good guide for assessing length of treatment, that is, the higher the initial VAS score the longer the expected duration of treatment. It does not, however, predict success of treatment.

Discussion

A recent review article in *Sports Medicine*⁷ by Constantinos et al. on the biomechanics and pathophysiology of overuse tendon injuries has identified the presence of intratendinous differential strains, with some parts of the tendon preferentially loaded and other parts "shielded". In general it is the "shielded" areas that are initially affected by tendinopathy. Alternatively, they say compression factors between bone and tendon at the enthesis, or thermal damage and injury may also be involved in the etiology of tendinosis. Exercise temperatures above the 42.5°C threshold viability for fibroblast have been recorded.⁸

The authors also argue that the traditional view of a tendon overuse injury as a result of tensile overload does not stand close scientific scrutiny and that mechanical "underuse" may be important in the etiology of tendinopathy which they describe as "an exaggerated dysfunctional repair response". This view of tendinopathy is similar to what Rolf et al. describe in the first and

only controlled study on the histopathology of patellar tendinopathy in *Rheumatology* in 2001.⁹ These authors interpret the hypercellularity, disturbance of the collagen matrix and increased proteoglycans found in tendinopathy as strongly suggestive of a "halt in the early phase of tendon healing, except for the absence of the inflammatory response". They also point out that although some authors regard tendinopathy as a degenerative disorder it also occurs in young people.^{10,11} In this respect it is interesting that patient TS, age 57 in this pilot study, sustained his initial Achilles tendinopathy at age seven when flying down hill on his tricycle, a birthday present. The right tricycle paddle hit his Achilles tendon at full speed causing a major contusion of the tendon at the time and chronic intermittent pain and disability for the next 50 years. He responded well to six prolotherapy treatments with considerable thinning of the tendon and reduction of his VAS score from 8 to 2 (3 at follow up).

Neovascularisation in Achilles tendinopathy was suspected to be part of the pain mechanism by the Swedish researchers Ohberg and Alfredson in their article "Ultrasound-guided sclerosis of neovessels in painful chronic Achilles tendinosis: pilot study of a new treatment."⁵ Nociceptive afferent ingrowth associated with the neovascularisation is postulated to be the

etiology of pain in tendinopathy.

The new vessels were located on the ventral and distal side of the Achilles tendon in the "stress shielded" areas⁷ of the tendon. These were sclerosed with Polidocanol resulting in significantly reduced pain levels.

Since the inception of prolotherapy by George Hackett⁶ in the 1940s, practitioners have maintained that rehabilitation of an incompetent structure, such as ligament or tendon by the induced proliferation of new cells, constitutes an effective treatment for musculoskeletal disability. Hence this pilot study's premise that inducing a physiological inflammatory/proliferative/remodeling healing response with the standard prolotherapy diluent dextrose 20% and lignocaine 0.1% will effectively strengthen an "incompetent" Achilles tendon, resulting in a lasting resolution of pain and dysfunction.

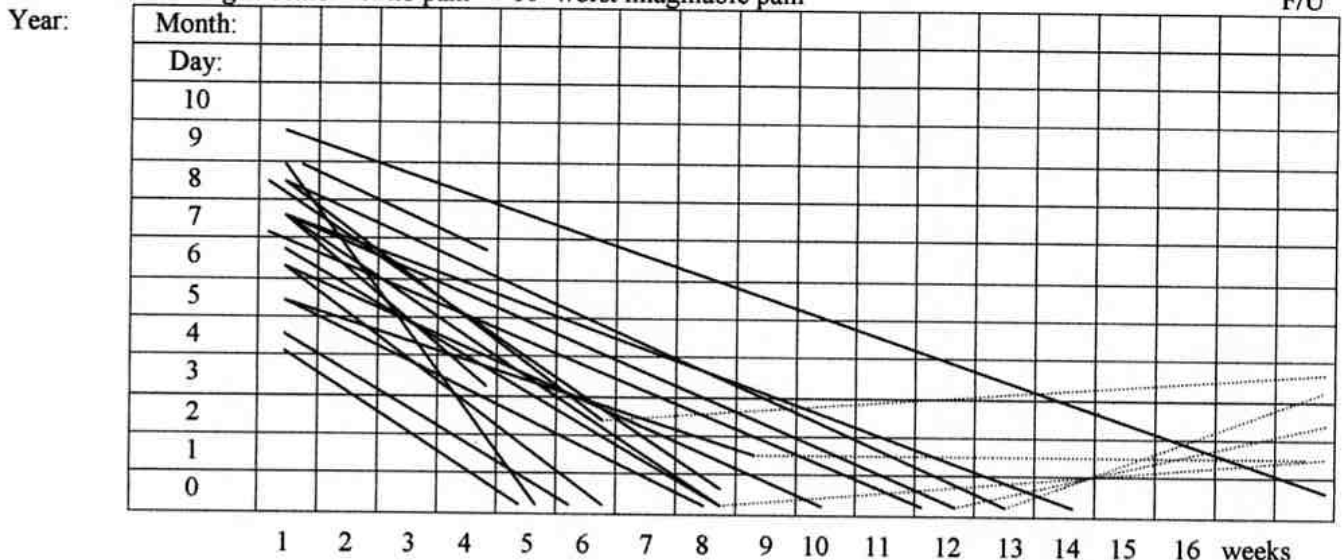
Discussion on the etiology of tendinopathy will no doubt be ongoing. The histopathology is, however, generally accepted.^{1, 9, 12}

The weakness of this study is the lack of a control group and short follow up. A suggested comparative trial of eccentric strengthening exercises, Polidocanol sclerotherapy, prolotherapy, and surgery with one-year follow up should answer many outstanding questions.

As the incidence of Achilles tendinopathy increases with age¹³ rec-

PROLOTHERAPY STUDY RECOVERGRAM

VAS: visual analogue scale 0=no pain 10=worst imaginable pain



ommended treatment protocols could be different for different age groups with different color Doppler flow imaging grading 0-3¹⁴ or ultrasonography grading 1-3.¹⁵

It is quite feasible that younger athletes with low grade tendinopathies may well respond better to an eccentric exercise regime than masters' athletes with an ultrasound grade 3 tendinopathy.

Surgery could then be delayed until all medical options were exhausted, as rehabilitation from surgery requires a lengthy rest followed by an intense exercise regime often lasting more than six months.

The use of recovergrams in clinical monitoring was first proposed by Dr Philip Watson in Australia in 2000.¹⁶ Pain VAS scores and disability scores are validated parameters in clinical monitoring.

This pilot study also demonstrated in the study recovergram an interesting connection between the initial pain VAS score and the number of required treatments, that is, the higher the initial VAS score the more treatments were needed. This was particularly evident in the patients with bilateral Achilles tendinosis with different initial VAS scores for left and right. The author has observed the same phenomena in bilateral lateral epicondylitis and knee pain and found this helpful in advising new patients on how many treatments they might need.

In conclusion, this pilot study shows the effectiveness of prolotherapy in Achilles tendinopathy and the benefits of clinical monitoring with a recovergram.

References

1. Khan KM, Cook JL, Kannus P, Maffulli N. Time to abandon the "tendinitis" myth. *Br Med J* 2002; 324: 626-27.
2. Puddu G, Kannus P, Postacchini F. A classification of Achilles tendon disease. *Am J Sports Med* 1976; 4: 145-50.
3. Bouchel R, Langberg H, Green S et al. Blood flow and oxygenation in Peritendinous Tissue and calf muscle during dynamic exercise in humans. *J Physiol* (London) 2000; 524: 305-13.
4. Kjaer M, Langberg H, Skovgaard et al. In

vivo studies of peritendinous tissue in exercise. *Scand J Med Sci Sports* 2000; 10: 326-31.

5. Ohberg I, Alfredson H. Ultrasound guided sclerosis of neovessels in painful chronic Achilles tendinosis: pilot study of a new treatment. *Br J Sports Med* 2002; 36: 173-75.

6. Hackett G. *Ligament and tendon relaxation treated by prolotherapy*. 3rd ed. Springfield, IL: Charles C Thomas, 1958.

7. Constantinos N, Maganaris, Marco V et al. Biomechanics and pathophysiology of overuse tendon injuries. *Sports Med* 2004; 34(14): 1005-17.

8. Wilson AM, Goodship AE. Exercise induced hyperthermia as a possible mechanism for tendon degeneration. *J Biomech* 1994; 27: 899-905.

9. Rolf C, Fu B S C, Pau A et al. Increased cell proliferation and associated expression of PDGFRB causing hypercellularity in patellar tendinosis. *Rheumatol* 2001; 40: 256-61.

10. Rolf C. Achilles tendon disorders: An overview. In *Controversies in Orthopedic Sports Medicine*, 1st ed., ed. Chan KM, Fu F, Maffulli N et al. Hong Kong: Williams and Wilkins, 1998, pp. 501-508.

11. Rolf C, Movin T. Etiology, histopathology and outcome of surgery in achillodynia. *Ankle Int* 1997; 18: 565-69.

12. Khan KM, Cook JL, Bonar F et al. *Histopathology of common tendinopathies*. Clinical Sports Medicine, 2nd ed.

13. Fahlstrom M, Lorentzon R, Alfredson H. Painful conditions in the Achilles tendon region in elite badminton players. *Am J Sports Med* 2002; 30(1): 51-54.

14. Serafin-Krol M, Czymy Z. Ultrasonography of Achilles tendon with color Doppler flow imaging. New possibilities in diagnostics of tendon pathology, preliminary results. Ultrashall 1999 Thema: Main lectures Surgery and Orthopedics.

15. Archambault JM, Preston W J, Bray RC et al. Can sonography predict the outcome in patients with Achillodynia. *J Clin Ultrasound* 1998; 26(7): 335-39.

16. Watson P. The Recovergram. *Australas Musculoskeletal Med J* 2000; 5(2): 24-28.